



PATIENT

Harlee Bitterman

SPECIES

Canine

BREED

Scottish Terrier

SEX

Female Spayed

AGE

13.8 years

WEIGHT

17.6lbs

INTERPRETED BY

Maggie Machen Lamy,
DVM, DACVIM
(Cardiology)

IMAGING PERFORMED BY

Jolee Stegemoller

HOSPITAL NAME

North Idaho Animal
Hospital (VCA)

REFERRING VET

Dr. Alexander Glasgow

INVOICE

46736

DATE

2/6/26

PRESENTING CLINICAL SIGNS

History: Grade 2/6 heart murmur. Assess prior to dental. CXR showed reverse D/right sided heart enlargement appreciated. Mildly hypertensive (even under sedation): 204, 157, 139, 179mmHg. -Abnormal PE/Chem/CBC/UA Results: CBC unremarkable, HW 4DX negative. ALP: 281U/L, UA WNL, USG 1.025.

ECHOCARDIOGRAM FINDINGS

2D, m-mode, color flow and doppler imaging is available. Mild diffuse thickening of mitral valve leaflets with no prolapse into the left atrial lumen. No mitral regurgitation with no left atrial dilation. Normal LV diameter with adequate myocardial function. The tricuspid valve is mildly thickened with septal prolapse and mild to moderate tricuspid regurgitation. Normal velocity. Mild right atrial enlargement. The pulmonic and aortic valves are normal in morphology and mobility. Normal pulmonic and aortic outflow velocities with laminar flow. No obvious aortic or pulmonic insufficiency. No pericardial or pleural effusion noted. No obvious cardiac masses.

CARDIAC CHART

CANINE CARDIAC PARAMETERS	MR VMAX (m/s)	TR VMAX (m/s)	LA/AO (Boon method)	LA/AO (Heart Base; Swe)	FS (%)	EF (%)	EPSS (cm)
NORMAL PARAMETER	4.5-5.5	<2.7	1.3	<1.6	28-40	40-100	<0.6
PATIENT	NA	2.0	1.3	1.6	32	62	0.3
CANINE CARDIAC PARAMETERS	HR (BPM)	AV VMAX (m/s)	PV MAX (m/s)	BODY WEIGHT (kg)	LA 2D short axis Base view (cm)	LVIDd Avg; 2D and m-mode short axis (cm)	LVIDs Avg; 2D and m-mode short axis (cm)
NORMAL PARAMETER	50-100	0.7-1.7	0.7-1.6	BELOW	BELOW	BELOW	BELOW
PATIENT	NM	1.0	0.5	8.0	1.9	2.2	1.5
*Normal chamber parameters expressed as a mean value (SD)				3	1.27 (5.3)	2.46 (2.46)	1.36 (5.5)
BODY WEIGHT DEPENDENT PARAMETERS				5	1.40 (4.5)	2.74 (5.2)	1.60 (4.7)
*Note: All measurements based upon multi-modal images and methods. An average value is reported.				10	1.50 (3.8)	3.27 (3.5)	2.06 (3.1)
				15	1.83 (2.0)	3.71 (2.4)	2.43 (2.1)
				20	2.02 (1.9)	4.14 (2.2)	2.80 (2.0)
				25	2.18 (2.4)	4.48 (2.9)	3.10 (2.5)
				30	2.33 (3.3)	4.83 (3.9)	3.39 (3.4)
				35	2.48 (4.3)	5.17 (5.0)	3.69 (4.5)
				40	2.62 (5.2)	5.48 (6.1)	3.96 (5.4)
				50	2.88 (7.1)	6.07 (8.3)	4.46 (7.4)

INTERPRETATION OF THE FINDINGS & FURTHER RECOMMENDATIONS

Chronic degenerative valve disease causing mild to moderate tricuspid regurgitation. Lack of significant right atrial enlargement indicates the current risk for complication is low. It is somewhat unusual to see TR in the absence of MR; however, pulmonary pressures are normal and no causative issues are seen. No concurrent issues such as mitral regurgitation are noted in this study.



PATIENT

Harlee Bitterman

SPECIES

Canine

BREED

Scottish Terrier

SEX

Female Spayed

AGE

13.8 years

WEIGHT

17.6lbs

INTERPRETED BY

Maggie Machen Lamy,
DVM, DACVIM
(Cardiology)

IMAGING PERFORMED BY

Jolee Stegemoller

HOSPITAL NAME

North Idaho Animal
Hospital (VCA)

REFERRING VET

Dr. Alexander Glasgow

INVOICE

46736

DATE

2/6/26

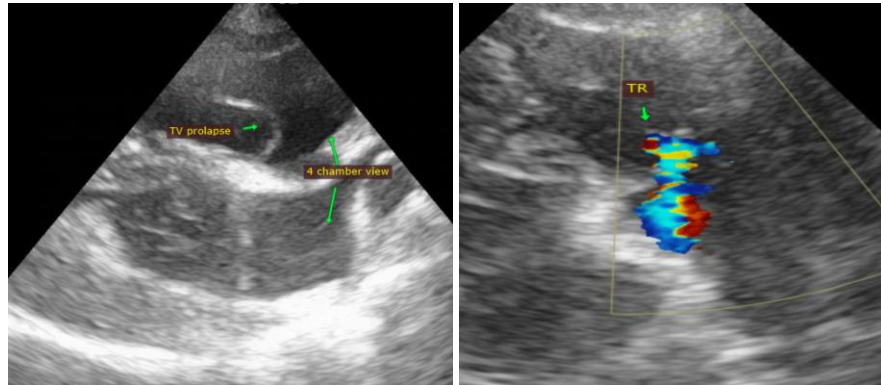
In an asymptomatic dog with no significant chamber enlargement, no cardiac medications are clearly indicated. Assessment of progression in the future will help predict long term prognosis, which is highly variable at this stage (B1). Omega fatty acid supplementation and mild salt restriction may be of some long-term benefit. Monitor for development of a cough, labored breathing, exercise intolerance or collapse episodes.

The reported blood pressures are too variable to interpret. Ideally obtain serial measurements in a controlled, low stress environment and continue until the readings plateau within 5mmHg of variability for 3+ readings.

No cardiac contraindication for general anesthesia.

Recommend conservative monitoring with a recheck echocardiogram in 6-12 months, sooner if any development of clinical signs.

IMAGES



The information and recommendations provided are based on the images presented by the referring veterinarian. No evaluation can be communicated regarding pathology that was not visible in the image/video clips provided.

Thank you for this referral. This report was generated using transcription software, and minor dictation errors may be present. If the clinical or image interpretation does not parallel your findings or if I can be of any further assistance, please contact me.

Maggie Machen Lamy, DVM
Diplomate of the American College of Veterinary Internal Medicine (Cardiology)
info@sonopath.com